



SUPER SERUM™ ADVANCE+ STUDY

scar maturation study

IMPROVEMENT IN SCAR TISSUE

STUDY OBJECTIVE Improvement in healing of a surgical wound was evaluated using SUPER SERUM™ ADVANCE+.

STUDY DESIGN

PART A - Identical surgical wounds were made on the right and left mid-thighs of a subject. A #15 surgical scalpel was used to make 1.5 cm full-thickness linear wounds extending into the adipose tissue. The wounds were sutured with 4 simple interrupted sutures of 5-0 nylon. The wounds were kept dry and plain Vaseline was applied to them 3 times daily for one week. Sutures were then removed. At that time, product application began on one side only with the other side serving as control. Normal daily showering/bathing was permitted but the wounds were not directly washed with soap. No products were applied to the wounds thereafter except for product to the treated side. Product was applied twice daily for 3 months and for another subsequent 3 months was applied once daily. Digital photos were taken at 3 months and 6 months.

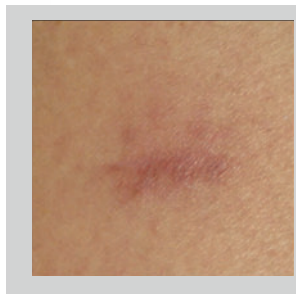PART B - Excisional surgical biopsy of both treated and control wounds in Part A occurred at 6 months. The biopsy specimens were sent to a dermatopathologist for microscopic examination. Photos of the histology were made.

PART C - Product was applied to one-half of a right mastectomy scar in a patient with multiple prior procedures through the same wound including mastectomy, reconstruction with implants, several revisions and finally implant removal. The remaining half of the same wound served as control. Product application began 10 weeks after the last incision occurred and was continued for 4 weeks. Digital photos were taken when product application began and after 4 weeks of product application.

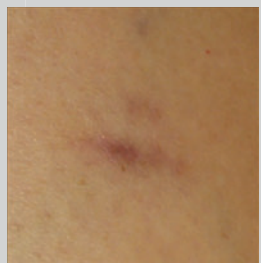SIGNIFICANCE OF STUDY Improvement in healing of surgical wounds would be useful in all types of skin incisions. Improved cosmetic appearance would have huge implications for cosmetic procedures. Improved physiologic healing is also sought to shorten healing time and possibly improve the strength of the wound.

RESULTS AND CONCLUSIONS Digital photos of the scars in both Part A and Part C treated with SUPER SERUM™ ADVANCE+ show improved cosmetic appearance of the surgical wounds treated with SUPER SERUM™ ADVANCE+. The scars appear much less visible with less overall scarred area including length and width. It is particularly significant that the mastectomy scar in Part C began use of product 10 weeks after the surgical procedure. This suggests that use of the product is also beneficial when use may be delayed by a significant number of weeks. Microscopic exams in Part B confirmed what was seen visually. Collagen bundles were more orderly on the treated side. The stratum corneum of the treated side exhibited no histologic indications of wounding. The stratum corneum of the control side was hyperkeratotic. The scar treated with SUPER SERUM™ ADVANCE+ had less chronic inflammation, much more orderly collagen bundles, a flat surface without hyperkeratosis and a fully basket-weaved stratum corneum that appeared like the stratum corneum in the adjacent non-scarred area.

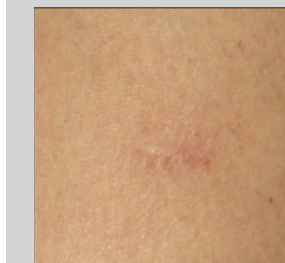PART A - SCAR MATURATION - DIGITAL PHOTOS



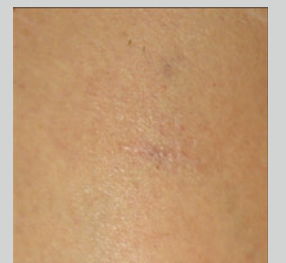3 months - Control



3 months with SUPER SERUM™ ADVANCE+ applied twice daily



6 months - Control



6 months with SUPER SERUM™ ADVANCE+ applied twice daily for the first 3 months and once daily for the following 3 months



SUPER SERUM™ ADVANCE+ STUDY

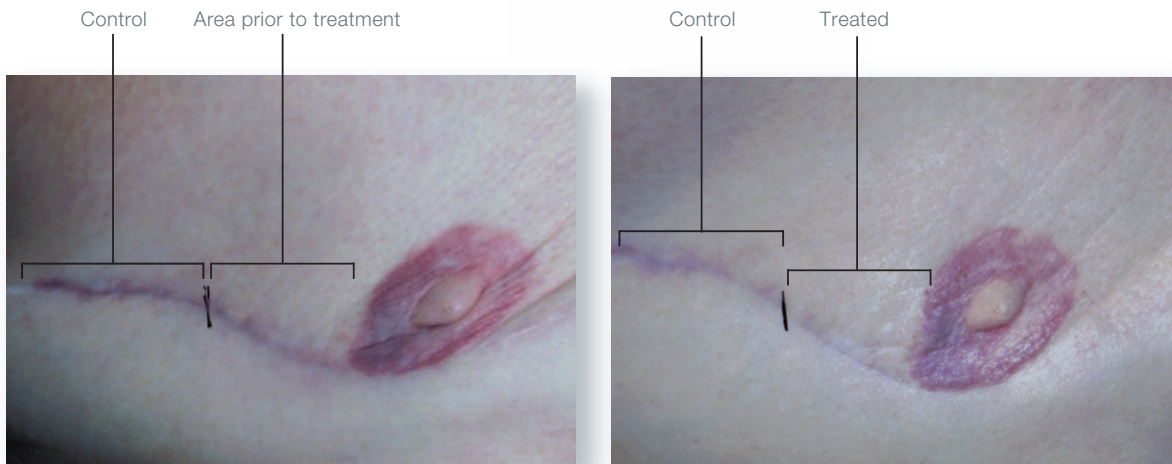
scar maturation study

PART B - SCAR MATURATION - TABLE OF HISTOLOGIC FINDINGS

The histologic comparison of the control and treated sides of Part A is given below in a table:

| | CONTROL | TREATED |
|---------------------|--|--|
| INFLAMMATION | 55-65 chronic inflammatory cells per perivascular space | Less than 50 chronic inflammatory cells per perivascular space |
| COLLAGEN | Collagen bundles in disarray, gaps between bundles | Collagen bundles regular and orderly, parallel bundles |
| SCAR SURFACE | Scar surface more elevated above skin surface, orthohyperkeratosis present | Stratum corneum fully basket-weaved, with same appearance as adjacent non-scarred area |

PART C - SCAR MATURATION - DIGITAL PHOTOS



10 weeks after surgery.
Before application of SUPER SERUM™ ADVANCE+

14 weeks after surgery.
Treated side has 4 weeks of
SUPER SERUM™ ADVANCE+ application